

39. Hatano T, Fukuda M, Shiotsuki H, Miwa H, Urabe T, Mizuno Y. Chronic inflammatory demyelinating polyneuropathy followed by systemic lupus erythematosus and Sjögren syndrome: a case report. *Rinsho Shinkeigaku* 2006;46:203–209.
40. Blaise S, Vallat JM, Tabaraud F, Bonnetblanc JM. Sensitive chronic inflammatory demyelinating polyradiculoneuropathy in Schnitzler's syndrome. *Ann Dermatol Venereol* 2003;130:348–351.
41. Kumazawa K, Sobue G, Okamoto H, Yuasa K, Mitsuma T. Two cases of chronic inflammatory demyelinating polyradiculoneuropathy (CIDP) associated with Graves' disease. *Rinsho Shinkeigaku* 1991;31:768–771.
42. Haq RU, Pendlebury WW, Fries TJ, Tandan R. Chronic inflammatory demyelinating polyradiculoneuropathy in diabetic patients. *Muscle Nerve* 2003;27:465–470.
43. Scherle-Matamoros CE, Negrín-Expósito A, Maya-Entenza C, Gutiérrez-Gil J, Pérez-Nellar J. Association between chronic inflammatory demyelinating neuropathy predominantly of the arms and penphigus vulgaris. *Rev Neurol* 2001;33:796–797.
44. Misawa S, Kuwabara S, Matsuda S, et al. Chronic inflammatory demyelinating polyneuropathy associated with idiopathic hemochromatosis. *Intern Med* 2006;45:871–873.
45. Emsley HC, Molloy J. Inflammatory demyelinating polyradiculoneuropathy associated with membranous glomerulonephritis and thrombocytopenia. *Clin Neurol Neurosurg* 2002;105:23–26.
46. Wilfong AA, Fernandez F. Myasthenia gravis in a child with sequelae of opsoclonus-myoclonus syndrome. *Can J Neurol Sci* 1992;19:88–89.
47. Spengos K, Vassilopoulou S, Christou Y, Manta P. Sarcoidosis in a case of MuSK-positive myasthenia gravis. *Neuromuscul Disord* 2008;18:890–891.
48. Watanabe H, Hakusui S, Yanagi T, Yoshida A, Yasuda T. A case of antiphospholipid syndrome associated with myasthenia gravis. *Rinsho Shinkeigaku* 1997;37:641–644.
49. Yasuda M, Nobunaga M. The association of myasthenia gravis and connective tissue diseases—the role of Sjögren's syndrome. *Fukuoka Igaku Zasshi* 1994;85:38–51.
50. Zivković SA, Medsger TA Jr. Myasthenia gravis and scleroderma: two cases and a review of the literature. *Clin Neurol Neurosurg* 2007;109:388–391.
51. Gowing EC, McKown KM. Myasthenia gravis in a patient with pauciarticular juvenile chronic arthritis. *J Clin Rheumatol* 2002;8:269–272.
52. Kanazawa M, Shimohata T, Tanaka K, Nishizawa M. Clinical features of patients with myasthenia gravis associated with autoimmune diseases. *Eur J Neurol* 2007;14:1403–1404.
53. Kiechl S, Kohlendorfer U, Willeit J, Pohl P, Vogel W. Myasthenia gravis and primary biliary cirrhosis. Common immunological features and rare coincidence. *Acta Neurol Scand* 1996;93:263–265.
54. Lossos A, River Y, Eliakim A, Steiner I. Neurologic aspects of inflammatory bowel disease. *Neurology* 1995;45(3 Part 1):416–421.
55. Csaplár M, Juhász M, Muzes G, et al. Association of coeliac disease and myasthenia gravis. *Orv Hetil* 2006;147:841–844.
56. Itoh K, Umehara F, Iwasaki H, Kanda A, Arimura K. A case of myasthenia gravis associated with systemic lupus erythematosus and pemphigus erythematosus. *Rinsho Shinkeigaku* 1997;37:111–114.
57. Wakata N, Kiyozuka T, Konno S, et al. Autoimmune thrombocytopenic purpura, autoimmune hemolytic anemia and gastric cancer appeared in a patient with myasthenia gravis. *Intern Med* 2006;45:479–481.
58. Valli G, Fogazzi GB, Cappellari A, Rivolta E. Glomerulonephritis associated with myasthenia gravis. *Am J Kidney Dis* 1998;31:350–355.
59. Purroy García F, Comabella M, Ragner N, Majó J, Montalban X. Lambert-Eaton Myasthenic syndrome associated with sarcoidosis. *J Neurol* 2005;252:1127–1128.
60. Tsuchiya N, Sato M, Uesaka Y, et al. Lambert-Eaton myasthenic syndrome associated with Sjögren's syndrome and discoid lupus erythematosus. *Scand J Rheumatol* 1993;22:302–304.
61. Mössner R, Tings T, Beckmann I, Neumann C, Paulus W, Reich K. A close look at autoimmune muscle disorders: association of Lambert-Eaton myasthenic syndrome with dermatomyositis. *Scand J Rheumatol* 2004;33:271–275.
62. Wirtz PW, Bradshaw J, Wintzen AR, Verschuuren JJ. Associated autoimmune diseases in patients with the Lambert-Eaton myasthenic syndrome and their families. *J Neurol* 2004;251:1255–1259.
63. Hoffman WH, Helman SW, Sekul E, Carroll JE, Vega RA. Lambert-Eaton Myasthenic syndrome in a child with an autoimmune phenotype. *Am J Med Genet A* 2003;119A:77–80.
64. Ozata M, Odabasi Z, Musabak U, Corakci A, Gundogan MA. A case of Addison's disease associated with the Lambert-Eaton myasthenic syndrome. *J Endocrinol Invest* 1997;20:338–341.
65. Takata T, Koide S, Ogata K, et al. Lambert-Eaton myasthenic syndrome associated with idiopathic thrombocytopenic purpura and diffuse panbronchiolitis: long-term remission after a course of intravenous immunoglobulin combined with low-dose prednisolone. *Am J Med Sci* 1999;318:353–355.
66. Timmermann L, Lindner V, Poepping M, Austermann K, Deuschl G. Idiopathic Lambert-Eaton myasthenic syndrome associated with minimal-change glomerulonephritis and psoriatic arthritis. *J Neurol* 2001;248:145–147.
67. Fung VS, Yiannikas C, Sue CM, Yiannikas J, Herkes GK, Crimmins DS. Is Sydenham's chorea an antiphospholipid syndrome? *J Clin Neurosci* 1998;5:115–118.
68. Paradise JL. Sydenham's chorea without evidence of rheumatic fever: report of its association with the Henoch-Schonlein syndrome and with systemic lupus erythematosus, and review of the literature. *N Engl J Med* 1960;263:625–629.

Fragile X-Associated Tremor/Ataxia Syndrome (FXTAS) with Myoclonus

Video



Fragile X-associated tremor/ataxia syndrome (FXTAS) is a neurodegenerative disorder that can affect carriers of a pre-mutation in the fragile X mental retardation 1 (FMR1) gene.¹ This gene normally contains fewer than 55 CGG triplet repeats. The full mutation (repeat number >200) is responsible for fragile X syndrome. Repeat lengths between 55 and 200 constitute a premutation which, besides being associated with FXTAS, also carries an increased risk of primary ovarian insufficiency (POI).^{2,3} Symptoms of FXTAS usually begin in the seventh decade. Major motor abnormalities are action tremor, cerebellar ataxia affecting limbs and gait, and Parkinsonism. Other possible features include cognitive decline, neuropathy, and autonomic dysfunction.⁴ The full phenotypic spectrum of FXTAS remains unclear. Although a broad range of neurological findings have been reported,⁴

Additional supporting information may be found in the online version of this article.

Potential conflict of interest: Nothing to report.

Published online 8 January 2010 in Wiley InterScience (www.interscience.wiley.com). DOI: 10.1002/mds.22929

myoclonus has not previously been described in association with this syndrome. We describe a man with FXTAS who, besides known features of this syndrome, also has generalized reflex myoclonus.

A 60-year-old man presented with a 2-year history of mild gait and balance difficulties. Past medical history consisted of treated hypertension and prostate cancer. Family history was notable for two sisters who experienced ovarian failure before age 35, and for the absence of mental retardation, parkinsonism, tremor, ataxia, or dementia. Examination revealed mild memory impairment (Mini Mental State Examination score 28 out of 30), and symmetric limb coordination deficits that included mild irregularity of timing and amplitude of rapid alternating hand movements, mild dysmetria on finger–nose testing, and moderate dyssynergia, evident as impaired checking response. There was mild gait ataxia, which was manifest as unsteadiness on rapid turning and inability to tandem-walk. There was mild bilateral hand action tremor on finger–nose testing and spiral drawing, and there were no parkinsonian findings. Generalized reflex myoclonus was present: tapping deep tendons in the arms or legs with a reflex hammer resulted in single jerks of the neck, trunk, abdomen, and arms. The same movements could be obtained by gentle pinprick of the palms or by scratching the palms or soles with a key (Video, Segment 1). Quantitative movement analysis revealed jerks that caused backward head movement, forward and upward abdominal movement (indicating trunk extension and/or diaphragmatic contraction), and bilateral shoulder elevation and elbow extension, which were time-locked to the stimulus (Fig. 1A). Calculation of movement onset latencies after pinprick of the left hand showed that the hands moved first (80–100 milliseconds), followed by head (100–120 milliseconds), and abdomen/trunk (140–160 milliseconds). Note that these latencies do not inform on the point of origin of myoclonus (cortex vs. brainstem vs. spinal cord) because they do not necessarily correspond to electromyographic signal latencies, due to differences in biomechanical properties of the moving body parts. No spontaneous jerks were observed at rest or during posture or action. Neuropsychological assessment revealed dementia consistent with a frontal subcortical and cortical pattern, including poor encoding and retrieval, severely impaired visual confrontation naming, and significantly reduced psychomotor and processing speed. Brain MRI revealed marked atrophy of the cerebral hemispheres, moderate cerebellar atrophy, and bilateral increased T2 signal in the middle cerebellar peduncles (Fig. 1B,C). FMR1 gene analysis revealed CGG trinucleotide repeat length 114, that is, in the premutation range (55–200).

This report is the first description of myoclonus in association with FXTAS. The motor manifestations of FXTAS suggest involvement of cerebellar and striatonigral pathways. Therefore, generalized reflex myoclonus, which is typically of cortical or brainstem origin,⁵ was unexpected. Whether myoclonus in this patient originates from the cortex or brainstem is unclear. His cognitive deficits fit the “frontal executive” pattern that has been described in FXTAS,⁴ and include a cortical component. The reflex nature of the myoclonus (Fig. 1A) and the severity of cortical atrophy (Fig. 1B) are consistent with a cortical origin. Moreover, cerebral volume loss has been reported in FXTAS and is correlated with CGG repeat length.⁶ Thus, diffuse cortical damage is a plausible substrate for myoclonus in FXTAS. However, vol-

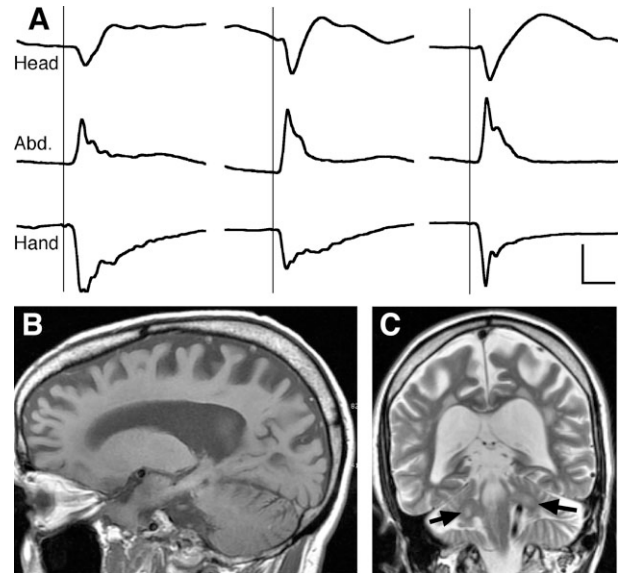


FIG. 1. A: Quantitative records of three examples of myoclonic jerks observed in the patient described in the present report. Position of head, abdomen, and left hand is plotted versus time. Traces show the response to three instances of pinprick stimulation of the hand (at times indicated by vertical lines), and illustrate generalized reflex myoclonus as time-locked jerks of the head (backward), abdomen (outward), and hand (down). Horizontal calibration bar: 0.5 seconds; vertical: 0.5 centimeters for head, 0.2 centimeters for abdomen, 1 centimeter for hand. Position was recorded at 110 Hz via an infrared motion capture camera (Proreflex MCU 500, Qualisys) with patient seated with arms flexed at the elbows. B: Sagittal T1-weighted magnetic resonance image illustrating cerebral atrophy out of proportion to cerebellar atrophy. C: Coronal T2-weighted image illustrating bilateral middle cerebellar peduncle hyperintensity (arrows).

ume loss in the brainstem also occurs in FXTAS,^{6,7} and thus a brainstem origin for the observed myoclonus cannot be excluded.

FXTAS is a rare cause of ataxia with a reported prevalence of only 1.5% of men with ataxia.⁴ However, clinical consideration and accurate diagnosis are essential because of the associated increased risk of fragile-X mental retardation syndrome and POI in family members. Besides demonstrating a new potential clinical feature of FXTAS, this case also highlights the fact that FXTAS can present with minimal tremor, and that family history of POI can be an important clue to the diagnosis. Establishing whether generalized reflex myoclonus is indeed a consequence of the FXTAS mutation, rather than indicating coincidence or a specific susceptibility in the patient described here, will require further clinical observation of individuals with this condition.

Legends to the Video

Segment 1. Selected examination findings in patient with FXTAS with reflex myoclonus. The video demonstrates generalized reflex myoclonus, dysdiadochokinesia (with mirror

movements in the other hand), mild intention tremor, dysmetria on finger step-tracking, impaired checking response, unsteadiness on turning, and impaired tandem gait.

Acknowledgment: We thank Dr. Toni Pearson for comments on this manuscript and Yaacov Rydzinski for video editing.

Author Roles: K. L. Poston: Conception, organization, and execution of research project, clinical data collection and review, writing of the first draft and review and critique of the manuscript; R. A. McGovern: Movement data collection and analysis, review and critique of the manuscript; J. S. Goldman: Clinical data collection and review, writing of the first draft and review and critique of the manuscript; E. Caccappolo: Clinical data collection and review, writing of the first draft and review and critique of the manuscript; P. Mazzoni: Conception, organization, and execution of research project, clinical data collection and review, movement data collection and analysis, writing of the first draft and review and critique of the manuscript.

Kathleen L. Poston, MD, MS
Robert A. McGovern
Jill S. Goldman, MS, MPhil, CGC
Elise Caccappolo, PhD
Pietro Mazzoni, MD, PhD*
*Division of Movement Disorders
Department of Neurology
College of Physicians and Surgeons
Columbia University
New York, New York, USA
E-mail: pm125@columbia.edu

References

1. Hagerman RJ, Leehey M, Heinrichs W, et al. Intention tremor, parkinsonism, and generalized brain atrophy in male carriers of fragile X. *Neurology* 2001;57:127–130.
2. Allingham-Hawkins DJ, Babul-Hirji R, Chitayat D, et al. Fragile X premutation is a significant risk factor for premature ovarian failure: the International collaborative POF in fragile X study—preliminary data. *Am J Med Genet* 1999;83:322–325.
3. Hagerman RJ, Leavitt BR, Farzin F, et al. Fragile-X-associated tremor/ataxia syndrome (FXTAS) in females with the FMR1 premutation. *Am J Hum Genet* 2004;74:1051–1056.
4. Berry-Kravis E, Abrams L, Coffey SM, et al. Fragile X-associated tremor/ataxia syndrome: clinical features, genetics, and testing guidelines. *Mov Disord* 2007;22:2018–2030; quiz 2140.
5. Cassim F, Houdayer E. Neurophysiology of myoclonus. *Neurophysiol Clin* 2006;36:281–291.
6. Cohen S, Masyn K, Adams J, et al. Molecular and imaging correlates of the fragile X-associated tremor/ataxia syndrome. *Neurology* 2006;67:1426–1431.
7. Brunberg JA, Jacquemont S, Hagerman RJ, et al. Fragile X premutation carriers: characteristic MR imaging findings of adult male patients with progressive cerebellar and cognitive dysfunction. *Am J Neuroradiol* 2002;23:1757–1766.

Stiff Person Syndrome as the Initial Manifestation of Systemic Lupus Erythematosus

Stiff person syndrome (SPS) is a rare neurological disorder characterized by the presence of fluctuating muscle rigidity and spasms of the trunk and proximal body parts.¹ In a significant number of cases, SPS is believed to be mediated by autoantibodies to glutamic acid decarboxylase (anti-GAD), limiting GABAergic activity and lowering the threshold for muscle spasms and other neuropsychiatric features of the disorder.² SPS with elevated serum anti-GAD levels may occur with other autoimmune disorders, specially insulin-dependent diabetes mellitus (IDDM).³ Ten percent of cases with normal levels of this antibody may be related to autoantibodies against amphiphysin, representing commonly a paraneoplastic syndrome.¹

Here, we report a case of SPS as the initial manifestation of systemic lupus erythematosus (SLE).

A 48-year-old woman with an 8-month history of painful bilateral thoracic and lumbar paravertebral muscles spasms. These spasms lasted from 10 to 30 seconds and were accompanied by severe pain that gradually disappeared over another 30 seconds. Contractions occurred spontaneously but were also elicited by anxiety and startle reactions. Symptoms occurred throughout the day and occasionally during sleep. In-between periods of exacerbation, she felt fluctuating discomfort and rigidity in the cervical, thoracic and lumbar axial muscles, including scapular girdle, leading to an almost persistent upright posture. During the previous 2 months, mild nonpainful facial spasms were noticed.

Past medical history was positive for depression, refractory to a 3-month trial of amitriptyline 75 mg qd and to current treatment with venlafaxine 150 mg qd. Family history was negative.

On examination, cranial nerves were normal except for increased startle responses after nose or facial tapping. Muscles were normotrophic and tone was normal in the limbs but moderately increased in the axial muscles. Strength was normal and deep tendon reflexes were brisk and symmetric. Cutaneous abdominal reflexes were decreased, plantars were flexor. Sensation was normal. Cerebellar signs were absent. Posture in the upright position showed the signs described above. Gait was slow with noticeable axial stiffness.

Routine laboratory exams included normal leucocytes count, with mild Coombs-positive anemia (Hb 10.3 g/dL) and thrombocytopenia (120,000/ml); normal fasting plasma glucose, hemoglobin A1C, creatinine, electrolytes, TSH and CK levels; erythrocyte sedimentation rate was 79 mm/h; negative syphilis, hepatitis B/C and HIV serologies; plasma anti-GAD levels were 12.6 U/mL (radioimmunoassay; normal 0–1 U/mL). Cerebral spinal fluid analysis was normal with no oligoclonal bands. Cranial and spinal cord MRI were unremarkable. Electromyography with nerve conduction studies revealed continuous activity of the lumbar paraspinal muscles.

Potential conflict of interest: Nothing to report.

Published online 13 January 2010 in Wiley InterScience (www.interscience.wiley.com). DOI: 10.1002/mds.22942